



SAO NEWS

IN THIS ISSUE

SAO LEADERSHIP

President

Dr. Sims Tompkins
Columbia, SC

President-Elect

Dr. Mark W. Dusek
Savannah, GA

Secretary-Treasurer

Dr. Preston Miller
Jackson, TN

First Senior Director

Dr. Debbie Sema
Birmingham, AL

Second Senior Director

Dr. Beth Faber
Tappahannock, VA

Third Senior Director

Dr. Eric Nease
Spartanburg, SC

Immediate Past President

Dr. Jeri Stull
Fort Thomas, KY

AAO Trustee

Dr. Richard Williams
Southaven, MS

AAO Trustee at Large

Dr. Alexandra Thomas
Spartanburg, SC

Director, The American Board of Orthodontics

Dr. Tim Trulove
Montgomery, AL

SAO CONTACT INFORMATION

32 Lenox Pointe
Atlanta, GA 30324
Phone: (404) 261-5528
Fax: (844) 214-1224
saoevents@saortho.org

President's Message Page 2
Dr. Sims Tompkins

SAO Leadership Update Page 3
Dr. Sims Tompkins

Greetings Fellow SAO Members Page 4
Dr. Richard Williams

SAO's 2020 Citizenship Award - Dr. Miller W. Gibbons Page 5
Dr. Kelly Goeckner

SAO 100th Meeting Report Page 6
Dr. Chris Howell

SAO Delegation Chair Report Page 7
Dr. Robert Moss

Life as a New and Younger Member Delegate Page 8
Dr. Tyler Rathburn

AAOPAC Page 9
Dr. Greg Inman

AAO Foundation Report Page 10
Jackie Bode

How Would YOU Treat This Patient? Page 11-14
Dr. Tim Shaughnessy

Counter Clockwise Page 15-19
Dr. Naurine Shah



President's Message

Dr. Sims Tompkins

As we start the third quarter of 2021, our regular routines and life in general seem to be getting back to a pre-Covid normal.

As people of all ages become vaccinated, more and more are venturing out and businesses are opening up. I, for one, am extremely happy that we can see the light at the end of the tunnel.

Things have been fairly busy with the SAO over the past several months and I want to update you on the work of your Executive Committee.

First, in April, Resolution 12-21 SAO/SWSO (S2-BT/S3-SAO) was passed in the AAO House of Delegates. This resolution states that the Southern Association of Orthodontists and the Southwestern Society of Orthodontists will merge as one constituent of the American Association of Orthodontists at the appropriate future time. For the past three years, the SAO and SWSO have been in consultation to blend the two organizations with a unified mission statement and strategic plan. We are well down the road at this point.

Second, as a result of this future merger, our Executive Director, Heather Hunt, has transitioned from the Executive Director position to a consulting role. We're grateful that Heather has spent the past seven years serving our association and our members as our Executive Director. In this time of transition, we have hired two partners: ZuBu Management Solutions will serve as the Executive Director Team and The Whiddon Group will serve as our Marketing Agency. The SAO has a long history of working with both of these businesses. The Executive Committee believes they are the best "fit" to assist us with our association and its management.

Third, we continue to finalize the details for our 100th Anniversary Meeting Celebration that will be held in Charlotte, NC from October 7 - 9, 2021. It has been an honor to serve as President for the SAO's 100th year. We are looking forward to getting back to some sort of normalcy with this in-person meeting. I want to thank Dr. Chris Howell, our annual meeting chair, for the hard work and dedication he has given to make our annual meeting a success. We will have an Opening Ceremony on Thursday, October 7, 2021 that will officially kick-off our 100 year celebration. As we began to shape

the theme for our meeting, we knew that we needed to focus on the pillars of our association - honoring our past, celebrating our accomplishments and creating a vision for our future. The SAO works diligently to assist our members and advance our specialty through education, advocacy, relationships, charity, governance, team building and much more. The SAO & YOU is our main focus! We thank you for making our association what it has become and we're excited about our future!

Be on the lookout for additional details about the meeting along with registration information, I hope to see all of you there! ■



SAO Leadership Update

Dr. Sims Tompkins

As mentioned in the President's Message, the SAO has a new leadership team.

This team is excited to work with all members and with SAO leadership. Each member of the team looks forward to seeing many of you at our October, 7 - 9 Centennial Celebration in Charlotte.



Lissette Zuknick
Executive Director

Lissette Zuknick has over 20 years of association management experience. She was born and raised in

Tampa, FL, home of the 2020 Stanley Cup and Super Bowl Champions, and received a business management degree from the University of South Florida. She enjoys board management, and helping boards achieve their goals. She loves working on various leadership driven projects and working alongside a strong and fun team! Serving as the Executive Director, Lissette looks forward to building relationships with state leaders who serve our SAO components. She is looking forward to the opportunity to meet many SAO members at the Centennial Celebration while everyone is having fun at our extended happy hours and social events!



Kelsey Bulnes
Director of Operations & Membership

Kelsey has over 10 years association management experience. Kelsey is a Certified Meeting

Planner (CMP). She is committed to provide exceptional assistance and guidance to each association as it looks for ways to elevate its meeting experience and member engagement. As she serves as the Director of Operations & Membership for the SAO, Kelsey is excited to explore opportunities to advance the association's goals. For the Centennial Celebration in Charlotte, Kelsey is excited about the Opening Ceremony, the Saturday Football watch party and every activity in between!



Jennifer Baker
Manager, Meetings & Technology

Jennifer Baker has a passion for working in association management. She started working

with the SAO in December. She was born in Kentucky and received her degree from the University of Kentucky (Go Cats!), but has lived in Atlanta, GA for the better part of ten years. She enjoys furthering the mission of the SAO by supporting each state component during its annual meeting. She will also manage many aspects of the SAO's annual meeting. She's most excited about meeting members face to face in Charlotte in front of the beautiful backdrops the city has to offer.



Jaclyn Whiddon
Director of Marketing & Communication

Jaclyn Whiddon started working in orthodontics over 20 years ago and has spent the last 15

as an orthodontic marketing consultant. She received a degree in Organizational Communication from Rollins College. Her passion for helping the SAO with marketing was initiated many years ago when one of her clients served as SAO President. She is very aware that it is important to create an excellent meeting filled with fun events, amazing lectures for the entire team and great opportunities for our exhibitors and sponsors. As she serves in this marketing role, Jaclyn is excited to work to enhance our communication with members and to market our Centennial Celebration in Charlotte. She is most excited about the Opening Ceremony with award presentations that celebrate a lifetime of achievement through selfless volunteer service. This is always a special moment!



Amy Hokkanen
SAO 2021 Meeting Planner

Amy Hokkanen started her career by working for Marriott on the supplier side of the hospitality

industry. She has a background in meeting/event planning for associations, non-profits, corporate and higher education in addition to her experience in association management. She enjoys cultivating relationships with meeting attendees while giving each attendee the best possible customer service! Amy is a proud graduate of The University of Georgia. Her degree is in Journalism. She joined the SAO team for the 2019 Joint Meeting with SWSO and is looking forward to continuing her work this year in Charlotte by managing the logistics during the week of the meeting. For this year's 100th Anniversary meeting, she is most excited about the fantastic event at the NASCAR Hall of Fame on Friday night. It will be a night to remember! ■



Greetings to Fellow SAO Members

Dr. Richard Williams

Greetings Fellow SAO Members! I am certain you can discern from all the news that the Covid pandemic has upset many plans.

It has created a need to very quickly change and adapt to the needs of the AAO and to the needs of AAO members.

We should be talking about what a wonderful venue we enjoyed in Boston, celebrating and reflecting on the successes of another great meeting.

This is not meant to be, however, since restrictions in the New England area were not conducive to holding a meeting the size of the AAO. The AAO staff was nothing short of amazing in their nimbleness and ability to move in a very short time to another virtual meeting with world class speakers and activities adapted to a virtual format.

There was, once again, an Innovation Pavilion at the annual session. This year's Innovation Pavilion helped us learn about the latest products and services to hit the market. From exhibitor lectures and connecting with suppliers in the virtual exhibit hall to discovering how AAO's TechSelect can help you bring in-house fabrication of aligners to your practice, the Innovation Pavilion was a pathway to learning about the latest developments in the industry.

About TechSelect: 3D printers and in-house fabrication of aligners are hot topics among orthodontists. AAO TechSelect is a learning resource with over 40 videos, guides, and interactive tools to learn how the entire process works, understand the costs involved and calculate the number of cases needed to payback the investment of setting up an in-house lab. Check it out: <https://techselect.aaoinfo.org/>

As a "knock-off" on Shark Tank, our virtual AAO meeting featured entrepreneurs who pitched their latest innovations.

Entrepreneurs presented their business plan to potential investors in the hopes of securing the funding they need to take their company to the next level.

As if adapting this year's meeting to a virtual format wasn't enough to keep our meetings department busy, the pandemic caused the state of Hawaii to take over and occupy a significant portion of the Honolulu Convention Center through the end of 2022. As a result, the AAO would have been significantly handicapped and the meeting could not provide the member experience we all desire. Dr. Dillehay and the AAO team have quickly pulled a "rabbit out of the hat" and have selected Miami to host us in 2022. The city leaders are excited to entertain our association. I am certain it will be a memorable chance for us to get back together for the first time since Los Angeles.

There is another new AAO product under development that will pilot later this summer. It is a practice accelerator program that is being developed

in partnership with the University of Pennsylvania's Wharton Business School. It is intended to provide our members with training in all aspects of business and will include, as part of the program, a private consultation specific for the enrollee's situation. Once the pilot is completed and tweaks are made to enhance the product, it is anticipated to be available to the first class of enrollees this fall.

Two items of interest that concern governance of the AAO are being considered. **SAO and SWSO have been involved in ongoing discussions, the goal is to develop a pathway for merger of the two constituents.** Conversations are far along with details continuing to be aligned between the two groups. Dr. Robert Moss has provided some information in his report that you may find of interest. The House of Delegates has created a Task Force with the Speaker and representation from the eight current constituents to investigate consolidation and/or reorganization of governance for the AAO. The consultant assisting is Mark Engle. Mark has been very helpful to the Board of Trustees and has helped your BOT create a path forward for the At Large Trustee positions.

The second item of interest is the At Large Trustee positions. We currently have two of the three available positions filled. It was determined at last year's House to leave the third position unfilled due to the uncertainty of the pandemic and its effects on the AAO. We are currently working on the parameters to seek an additional member for this role. An announcement to seek applicants is anticipated in early fall. Please be on the lookout if you feel you have interest.

I would be remiss if I didn't tell everyone how much I am looking forward to the Charlotte SAO meeting to celebrate our 100th year. There are many reasons for this but the primary one is to once again be in the physical presence of my Southern Family. Our relationships are an important part of who we are and this virtual stuff is just not the same! See you soon and thanks for the privilege to serve! ■

SAO's 2020 Citizenship Award

Dr. Kelly Goeckner



Dr. Miller W. Gibbons

Miller W. Gibbons grew up in "The World's Greatest Tobacco Market" of the nineteenth century: Wilson, North Carolina. Miller was an outstanding football player for Fike High School where he was later inducted into the athletic hall of fame. He continued his football journey down Tobacco Road, playing at the University of North Carolina at Chapel Hill his freshman year. He bleeds Tar Heel blue and would stay for both dental school and orthodontic residency.

He met and married his wife, Becky, while at UNC-Chapel Hill, and they returned to Wilson in 1982 to open his orthodontic practice. Now nearly 40 years later, he continues to reside in Wilson with Becky, his three accomplished children (pharmacist Walton, dentist Kate and CPA David) and two wonderful grandchildren (William and Virginia). Miller always felt Wilson is an ideal place to raise a family and is thrilled all of his kids are still local.

Throughout his career he was an active member of the North Carolina Dental Society, American Dental Association, North Carolina Association of Orthodontists, Southern Association of Orthodontists and American Association of Orthodontists. He served as the chairman of the North Carolina Dental Society Council of Dental Practices and Dental Education, chairman of the North Carolina Dental Society Health Care Plan and Trust and chairman of DOTS. Locally, he was the chair of the Wilson County Dental Society and secretary for the 85 Study Club. Dr. Miller Gibbons is revered as a wonderful colleague and friend by all local dental professionals.

Wilsonians know Dr. Gibbons as 'Miller,' a most incredibly kind man who is generous with both his time and his talent and always with a friendly smile. Miller was president of the Fike high school's booster club and coached youth athletics. He dedicated time and treasure to his community by serving on the YMCA Board, Wilson Chamber of Commerce, Boys and Girls Club of America and as a chairman of the Wilson Education Partnership. Most notably, his passionate involvement with First United Methodist Church and the Salvation Army defines his servant leadership. Few may see the immense amount of work he continues to contribute to these organizations, but thousands benefit from his efforts.

Miller served on the Salvation Army Advisory Board for over thirty five years and has acted as both treasurer and chair. Miller embodies the Salvation Army's mission of service: 'to meet human needs without discrimination', and you can guarantee that you will see Miller ringing a bell for donations each holiday

season. He has irrepressible energy that kept donations strong and would make time during patient care hours to attend meetings. At one point Miller fought to keep a dissolving board together and has represented the local chapter on state and national board committees.

Miller and his family have been active members of the First United Methodist Church and his pastor reports that he has served on every committee the church has had over the decades. He has been a Sunday school teacher and youth counselor for twenty-six years. He has been chair of the church's council and is currently serving as the chair of the First United Methodist Church Endowment Committee. This committee, in its few years of infancy, has already raised hundreds of thousands of dollars for areas of mission and mercy within the Wilson community.

It is without doubt that Miller has a servant's heart and leads his community by example. While receiving little recognition, Miller has likely changed just as many lives outside the walls of his orthodontic practice as he has in his thirty-eight years of patient care. Dr. Miller W. Gibbons most deservedly received the SAO's 2020 Citizenship Award for his life-long commitment to bettering his profession and his community.

Recently retiring from full-time orthodontic practice, he has been happily working on being the best 'Papi' and continues to live and serve the community which is so dear to his heart. Miller can often be seen running with his dogs and always stops to say hello to the generations of patients he meets around town. Miller enjoys spending time at the beach with Becky and his family and continues to cheer on the Tar Heels every chance he gets. ■

Meeting Chair Update: SAO Annual Session 2021

Centennial Celebration in Charlotte



Dr. Chris Howell
2021 Meeting General Chair


Together is a wonderful place to be!

We know Charlotte will be the perfect destination for this celebration. After the year we've had, we realize now more than ever that **TOGETHER** is a wonderful place to be - the awesome city of Charlotte is just the cherry on top!

I've had the pleasure to plan our Centennial Celebration with Dr. Sims Tompkins whom I have known for many years. We selected the perfect location to match 100 years of southern charm with the chic sophistication of modern times. We invite you to join us at Le Meridien in Charlotte, NC as we come together - finally - to toast our rich history!

We have an amazing line up of speakers for our annual session with something for everyone on your team. Visit the SAO website to see the full lineup of dynamic speakers. Some of our practice management focused presenters include Mr. Timothy Donoghue and Ms. Debra Nash. Each will present on various topics related to improving your practice, growth, customer service and post COVID changes. Our clinical presenters include Dr. Eric Wu, Dr. Mazyar Moshiri, Dr. Scott Frey and Dr. John Warford. Their engaging presentations will include aligner therapy, dental monitoring and virtual visits, Deep Bite and Class III Invisalign Correction and much more.

We plan to open our 100th Meeting with a grand opening ceremony to which everyone is invited! This is the perfect way to kick off our celebration! Thomas Dismukes, our keynote speaker, will give an engaging and memorable presentation. We will recognize and celebrate our peers as we present awards and honors to those who have served our association selflessly.



Centennial Celebration of the
Southern Association of Orthodontists

SEE YOU IN CHARLOTTE • OCTOBER 7-9, 2021

We're going to have fun, lots of fun! The SAO always knows how to have a good time, but I assure you that this 100th celebration is packed full of fun! You won't want to miss our night at the NASCAR Hall of Fame! This truly is an event to bring the whole team and family. Everyone will find a way to have fun in this interactive facility. We hope to see you there. Sims and I personally challenge you to a race to see who will finish first! It's going to be a great time! There will be happy hours, socials, tasty breaks throughout the lectures and much more. We will end our meeting with a Saturday afternoon filled with football, so join us on Saturday to wrap up a successful event with even more fun.

Please join us in Charlotte to celebrate 100 years of friendship, collaboration, history and innovation. There is no better time to be **TOGETHER** than now!

Start your engines. We'll see you at the finish line! ■

As was the case in 2020, the pandemic forced the House of Delegates to convene virtually in 2021.

AAO HOD meets Virtually – Again

With the experience and knowledge gained from an abbreviated schedule and limited business in 2020, the 2021 VHOD more closely resembled a face to face meeting with the normal 2 constituent caucuses, 3 reference committees and a full slate of business.

However, all business was combined into one session - one looong session! Two resolutions consumed the majority of delegate time and efforts: the proposed revisions to our Clinical Practice Guidelines, and resolutions related to the merger of the SAO and SWSO.

Early in the process, when the SAO delegation met in Atlanta for the March ad interim board meeting, there were 26 resolutions and the Clinical Practice Guidelines revisions were creating quite a stir. The Clinical Practice Guidelines document is reviewed and revised, as needed, biannually. The focus this year was to make the document more "outward versus inward". By the end of that weekend, the rationale for the Guidelines changes as well as the resistance to change were well known. Our trustee, Richard Williams, chaired an AAO committee that was charged with reviewing the CPG's. During the time between the SAO ad interim and the virtual HOD, Richard worked with delegation chairs, and the committee to add and clarify language in the final document. As just sent out in an AAO eBulletin, two important messages are in the newly adopted document: 1) orthodontic treatment involving teledentistry should include certain protections for patients, and 2) these guidelines apply to ANYONE providing orthodontic treatment. A copy of the Clinical Practice Guidelines along with a cover letter was sent to all state boards of dentistry.



Dr. Robert Moss
SAO Delegation Chair


After the issues with the Guidelines seemed to be under control the focus shifted to SAO's resolution to continue the merger process with SWSO. After several attempts at substitute resolutions from other constituencies, the final version was very similar to the original, with the final modifications coming from us. Resolution 12-21 SAO/SWSO, (S2 BT) (S3-SAO) was adopted on a 56-7-1 vote!!!! As part of the give and take of the process, SAO agreed to a resolution to form another committee to look globally at AAO governance.

One of the main functions of the House is financial policy, budget, dues and all spending programs. **A balanced budget was adopted again this year with NO dues increase.** The SAO substitute resolution to raise our Consumer Awareness Program assessment \$100 (300 to 400) was adopted after the original resolution for a \$150 increase was defeated.

Our SAO delegation put in many hours, including the last session on a Sunday afternoon in April, but our efforts were rewarded! Just prior to adjourning, it was a privilege to recognize our own Jeff Ricabaugh, who for the last 3 years has guided the HOD and the AAO through all of the difficulty of dealing with canceled annual sessions, canceled HODs, figuring out how to make our necessary business happen through a virtual process, adapting and readapting and then sometimes doing it over again. Jeff, the AAO will miss the leadership you provided as Speaker of the House! Thank you again for representing the SAO in such a magnanimous fashion! ■

Life as a New and Younger Member Delegate

Dr. Tyler Rathburn



The desire to give back professionally was instilled in me as a resident at Augusta University. Our department chair, Dr. Eladio Deleon, always preached the necessity of not just being a good orthodontist, but an involved one as well. He led by example.

He was serving as the President of The American Board of Orthodontics while I was a resident. As residents, we attended as many organized meetings as we could and never tired of the experiences. One of our faculty members at the time was Dr. Robert Moss. I was always shocked by how much he knew about the inner-workings of the AAO. As I would come to find out, Dr. Moss was the chair of the SAO delegation and a key figure during my years as the New and Young Member delegate.

I also took a cue from my mother Dr. Melisa Rathburn and stepfather Dr. Michael Stewart, both orthodontists, each of whom eagerly served the GAO and SAO throughout their years of clinical practice.

I truly believe that being involved is the only way to move our specialty forward and through the challenges it faces.

Nearly four years ago, only a few years after I started my clinical practice, I felt the urge to do what I could to serve the AAO. I approached Heather Hunt and simply asked, "Is there anything that I can do? I would love to help." Within the week, she was back to me with multiple opportunities. It reminded me of what my stepfather always said, "Sometimes, all you have to do is ask. If you are interested in helping - just ask!"

To be honest, I was not entirely sure what I was in for. I knew I wanted to help, but I confess, even though I knew Dr. Moss, what I would be doing for the delegation in my AAO role was foggy at best.

Lucky for me - I could not have met a friendlier or more helpful group of people to guide me through the process.

It was clear from the very beginning that even though I was both a "New" and a "Younger" member of the delegation, I was considered to be one of its own. In fact, I later learned that the role of a New and Younger delegate was a position that was created specifically by the SAO as a new initiative to involve new and younger members in AAO leadership. As I would come to find out, this is one of the primary challenges that the AAO faces. The SAO didn't just pay lip service to this idea, it acted. After serving on the delegation, I feel the motto of the SAO delegation is "actions speak louder than words."

During my first year on the delegation, I listened far more than I spoke. It was a steep learning curve. But with the help of the other SAO delegates and chairs, I gradually learned the ropes and structure of the AAO, its various committees, rules and procedures, and the way policy is

acted upon. I found it fascinating and quickly realized both how hard-working and committed SAO leadership is to any task. There were long hours, long discussions, and thoughtful proposals all around. I was asked for my opinion and, though a bit intimidating at first, was able to participate fully and even vote on the delegation floor.

Interestingly, my very first year was full of important decisions for the AAO. Of primary interest was the funding and revamping of the Consumer Advocacy Program (CAP) as well as a proposal to add a New and Younger member to the Board of Trustees of the AAO. All in all, the year was a resounding success for the SAO delegation. In the two years that followed I was able to participate more fully; I even helped write an amendment to a bill the SAO had proposed. It was voted on and actually passed!

My only wish is that more of our members could witness what I saw "on the inside" of the delegation room. I feel that the AAO, and in particular the SAO delegation, is continuing to make strides toward making the process more and more transparent. I truly cherish the friends I have made along the way and my only regret is that I couldn't serve longer!

I am honored to have had the opportunity to serve as the SAO's first New and Younger member delegate but I know that the SAO is in great hands as it moves forward with Dr. Angie McNeight. I am confident she will do great things and make the SAO membership proud! ■



AAOPAC

Dr. Greg Inman

Hard to believe that it has been over a year since we “re-opened” our doors for in-person care of our patients.

Since that day, many of you have worked tirelessly to catch up on lost time. As well, your AAOPAC and the AAO Advocacy team have continued to work hard for the members of the AAO.

Federal level advocacy is made possible by the AAOPAC. Over the past year, the AAO has worked with its federal lobbying team at Cozen O’Connor Public Strategies to achieve many victories. These include:

- Successfully advocated for small business relief, including the Paycheck Protection Program (PPP) and the Economic Injury Disaster Loan (EIDL) program in the various COVID relief packages.
- Lobbied the Department of Health and Human Services (HHS) on the Provider Relief Fund (PRF) to ensure orthodontists were among the providers eligible for COVID funding. AAO also advocated on behalf of orthodontists to ensure orthodontists could be eligible for these funds.
- Engaged with various regulatory agencies to obtain guidance and clarification for COVID-19 safety protocols.

- Worked with leadership from the Occupational Safety and Health Administration (OSHA) and Department of Labor (DOL) to share best practices for keeping dental staffs safe, as well as to impact safety guidance for dentistry.
- Collaborated with the American Dental Association (ADA) and the Federal Emergency Management Agency (FEMA) to secure PPE for dentists across the country.

The Ensuring Lasting Smiles Act (ELSA) was reintroduced in March. Currently the Act has 230 co-sponsors in the House and 36 in the Senate! ELSA would require all group and individual health plans to cover medically necessary services related to the diagnosis or treatment of a congenital anomaly or birth defect. It addresses coverage denials and ensures that all patients receive the treatment needed.

Student Loan Relief and Student Debt Relief continue to be a main priority for the AAO. The Biden Administration has indicated its interest in tackling the student loan issue. The Student Loan Refinancing and Recalculation Act would preserve the in-school interest subsidy, reduce origination fees and rates, provide for refinancing, and allow for residency deferments. Today’s average debt for a graduating orthodontic resident is \$428,150, so you can see why this issue continues to be so important to the AAO and AAOPAC.

Thus far in 2021, only 37 SAO members have contributed almost \$18,000 to the PAC. This seems low when one considers how quickly the federal government can negatively affect each of our professional lives. I know that a lot of SAO contributions come in while members attend state meetings or the annual session, so I look for our numbers to rise.

To contribute to AAOPAC, please go to the AAO Member Website at www2.aaoinfo.org/advocacy/aao-pac/ or simply scan this QR code.



Lastly, the AAO just welcomed a new Director of Advocacy, Nathan Mick. Nathan lives in Lexington, KY and will be working remotely from home. He will take on the role of COGA liaison. The Advocacy Team continues to grow and looks to work hard for each of you. Please consider a contribution so we can be successful in all of our “battles” on the Hill and in your home state. ■

AAO Foundation Report

Jackie Bode



- We invite all AAO members to support the foundation by making an annual donation.
- The AAOF has a new expanded mission to support all our recently acquired programs and initiatives in 2021.



ONE PLACE, MORE OPPORTUNITIES FOR MEMBERS

Along with a new mission, the American Association of Orthodontists Foundation is now offering more opportunities for AAO members to get involved. In 2021, the AAOF welcomed the Donated Orthodontic Services (DOS) program and the Disaster Relief Fund (DRF) to its philanthropic umbrella so members can engage on multiple levels, all in one place.

The new mission, "The AAO Foundation is to advance the orthodontic specialty by supporting quality education and research that leads to excellence in patient care, and by promoting orthodontic charitable giving."

The AAOF's passion for education and research, will always be at the forefront of what it does. Expanding the mission statement and gaining two dynamic programs truly gives the Foundation new ways to move the specialty forward. Both programs, DOS and the DRF, will bring diversification to the Foundation by adding volunteerism and a way of supporting our members, especially during times of natural disaster.

To learn more, please visit:
www.aaofoundation.net/charitable-giving

2021 AAOF AWARDS PROGRAM

The Planned Awards Review Committee (PARC) met virtually to review the proposals for grant funding that were submitted. In March, the award winners were notified. 33 grant proposals were approved for funding this year. To learn more about the grants that were approved, please visit our website at www.aaofoundation.net/awards-program/about-the-aaof-awards-program

AAOF AT THE VIRTUAL AAO MEETING

The AAOF is proud to have supported the virtual meeting where the following award winners were honored:

The 2021 **Blair Award** winner is
Dr. Lee Graber from MSO.

The 2021 **Jarabak Award** winner is
Dr. Laura Iwasaki from PCSO.

Please join us in congratulating them for receiving these honors!

REMEMBER THE AAO FOUNDATION IN YOUR CHARITABLE GIVING

The AAOF website can now accept online donations! Please consider making an online donation to the foundation in 2021 by visiting our website. If you are interested in becoming a monthly donor, please consider joining the Century Club. This is for donors who give a minimum of \$100 a month to the AAO Foundation. You can sign up for this option on our website. Also keep the AAO Foundation in mind as you create your estate plans. If you have the AAOF in your will, as a beneficiary on your retirement plan, mentioned in your trust, etc. please notify the AAOF staff office so we can properly steward your donation as a Keystone Society member.

FOR MORE INFORMATION

If you should have any questions or concerns, please call **Jackie Bode, AAOF Senior Vice President**, at 314-292-6546 or by email jbode@aaortho.org ■

How Would YOU Treat This Patient?

Dr. Timothy Shaughnessy

A healthy and active 55 year-old woman presented for a second opinion. She recently began wearing aligners in the mandibular arch, provided to her by her general dentist. Three years prior to aligner therapy, tooth #25 was lost. Traditional root canal treatment and a secondary apicoectomy served this tooth well for decades before failing (Figure 1). The dentist was now recommending the extraction of adjacent tooth #26 because she observed increased mobility. This prompted the patient to check with two orthodontists prior to agreeing to the loss of an additional tooth. I found that the mandibular right lateral incisor was not compromised periodontally. More likely, the mobility was a function of active tooth movement with the aligners. I recommended that the patient cancel the appointment later in the day for the extraction. Furthermore, I encouraged her to consider comprehensive orthodontic treatment with fixed appliances in order to address all of her orthodontic needs, settle on a treatment plan, and ideally prepare her for restorative treatment to follow. She returned two weeks later for INITIAL records.

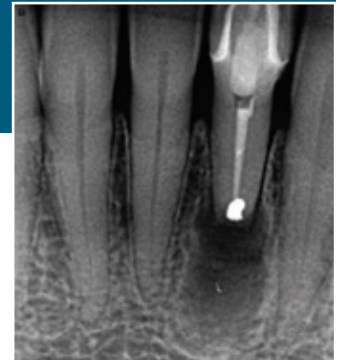


Figure 1: Traditional root canal treatment and a secondary apicoectomy

The INITIAL facial photographs (Figure 2) reveal a well-balanced face in both frontal and profile appearance. The lips are pleasing and competent. Upon smiling, the maxillary midline is slightly to the right of the mid-facial axis. The maxillary central incisor proximal contact relationship is also angled to the patient's right. This is a reflection of the mild cant of the maxillary occlusal plane. There is a slightly greater amount of posterior tooth and gingival display on the left side versus the right side. The ectopic maxillary left canine position camouflages this posterior vertical asymmetry.

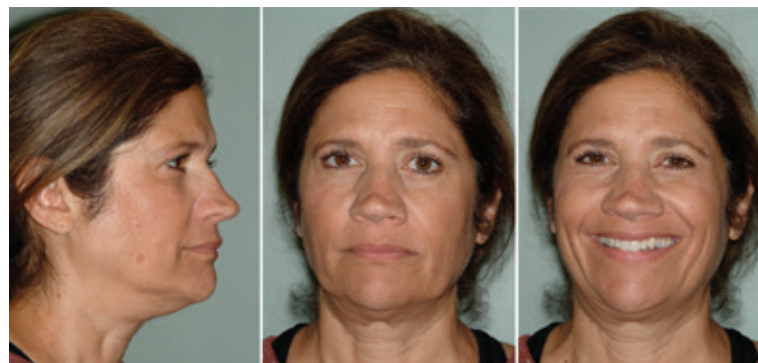
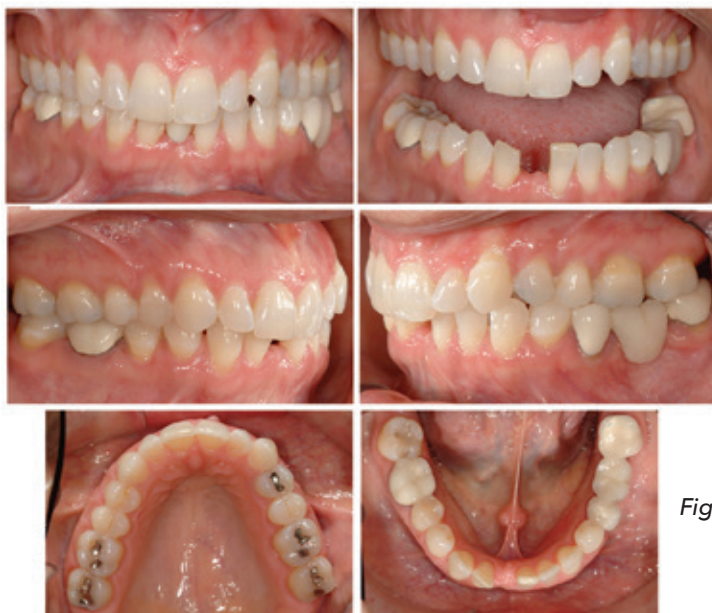
Figure 2: Initial facial photographs



The INITIAL intraoral photographs (Figure 3) show crowding primarily in the maxillary left lateral incisor and canine area. There is obvious spacing in the mandibular arch from the extracted incisor. Additionally, the left first molar is missing and has been replaced with a fixed bridge. There is a unilateral left Class II molar and canine relationship, resulting in an asymmetry in the anteroposterior plane of space as well. The fixed bridge was fabricated in crossbite, creating an asymmetry in the transverse dimension. It is significant to note that there is Bolton tooth-size discrepancy, characterized by small maxillary lateral incisors. Noteworthy also is the fractured mesial incisal edge of the mandibular right lateral incisor, which may require restorative alteration and play a role in the ultimate tooth size relationship.

Figure 3: Initial intraoral photographs

The panoramic radiograph (Figure 4) also highlights the fractured incisal edge of tooth #26, something the patient reports not noticing until after the adjacent tooth was extracted. The mandibular right first molar has had successful root canal treatment and a crown. All third molars were extracted decades earlier. This patient's overall periodontal bone support is excellent. The cephalometric radiograph and analysis (Figure 5a and 5b) confirm a Class I skeletal relationship with normal vertical dimension. The mandibular border double imaging suggests the likelihood of compensatory adaptation to the maxillary occlusal cant because no functional shift was detected clinically.

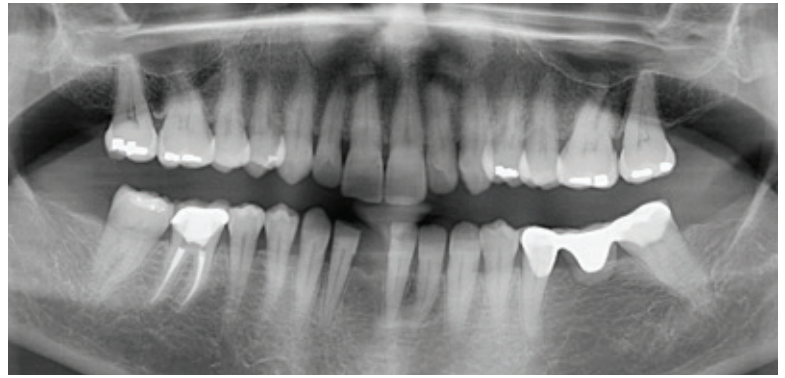


Figure 4: Initial panoramic radiograph

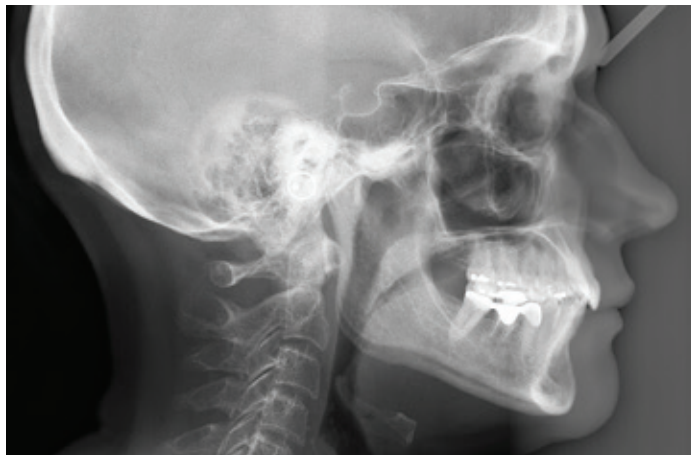

Figure 5a: Initial cephalometric radiograph

Value	Norm	Std Dev	Dev Norm
86.6	82.0	3.5	1.6 *
82.9	79.0	3.5	1.0 *
4.3	3.0	2.0	0.8
92.3	95.0	7.0	-0.5
100.7	102.0	5.5	-0.3
63.3	67.0	5.5	-0.7
1.4	2.7	1.7	-0.6
28.4	32.0	3.2	-0.9

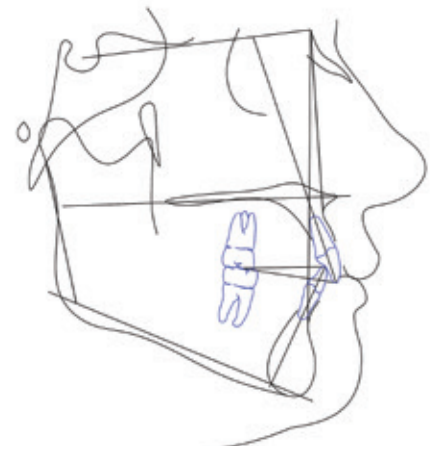


Figure 5b:
Initial cephalometric analysis

How would YOU treat this patient?

Treatment Planning

This patient wants to confirm the need to extract another mandibular incisor. Not only am I unable to immediately approve of extracting tooth #26, it is possible that the treatment plan chosen may include orthodontic space closure of the existing mandibular incisor space. Minimally, an evaluation of diagnostic records and comprehensive treatment planning is required to consider the various options. The patient was also intrigued by the possibility that her maxillary teeth could be aligned and her bite corrected if she switched from limited alignment of the mandibular incisors to comprehensive orthodontic treatment. The treatment plan chosen could make the general dentist's current aligner treatment and the plan to restoratively replace the missing tooth unnecessary.

There are three significant considerations in planning treatment. First, what is the best way to address the tooth-size discrepancy? Is the patient concerned with the size of her maxillary lateral incisors? Should space be created around these teeth for restorative

enlargement? Alternatively, might the patient favor space closure in the opposing mandibular arch and avoid restorative space closure of the missing central incisor?

Second, is it necessary to extract a tooth in the maxillary left quadrant for Class II correction and resolution of crowding? Opening space for maxillary lateral incisor restorative enlargement certainly favors the asymmetric extraction approach. However, non-extraction treatment in the maxilla as part of any treatment option, would worsen the midline discrepancy and increase overjet.

The third consideration in planning treatment is the skeletal asymmetry. Is it possible to correct the dentition and accept the skeletal relationship? Would surgery be required to correct the occlusal plane cant? Could a temporary anchorage device be placed in the maxillary left posterior quadrant to assist in intrusion, as well as Class II dental correction?

Option 1:

Plan to replace the mandibular right central incisor as the general dentist initially intended. However, as part of comprehensive treatment, extract the maxillary left first premolar only, to align the adjacent anterior teeth and produce left Class I canine occlusion. The Bolton discrepancy would then be resolved by restoratively enlarging the maxillary lateral incisors.

Option 2:

Orthodontically close the mandibular incisor space and accept the size of the patient's maxillary lateral incisors. This plan would greatly reduce the restorative needs of the patient following orthodontics. It is understood that the fixed bridge will be replaced as part of any treatment plan. The maxillary left first premolar would also be extracted for the reasons above.

A surgical option was suggested as a possibility by another orthodontist. The patient could not describe the details of that treatment. Although the patient does have a cant to her occlusal plane, she is not aware of it. It is not severe enough to affect her appearance or function. Dental correction could be achieved without surgery, without a temporary anchorage device, and with a much more favorable risk-reward ratio.

The Treatment Plan Chosen

The patient initially presented with no concern regarding the size of her maxillary anterior teeth, only that they were misaligned. The option of closing the mandibular central incisor space orthodontically was well received. Just a few weeks earlier, the patient was determining if she would need to replace one incisor or two.

.018 traditional twin brackets were placed on all of the maxillary teeth following the extraction of the maxillary left first premolar by an oral surgeon. The patient decided to switch to a different general dentist who segmented the bridge in the mandibular left quadrant. Independent tooth movement of the abutment teeth would permit left posterior crossbite and Class II correction. Brackets were placed on the mandibular teeth shortly thereafter. Round nickel titanium arch wires were used for initial alignment, followed by rectangular arch wires of the same material. A unilateral left closing loop arch wire was fabricated and placed in the maxilla for extraction site closure. Space closure in the mandibular incisor area was accomplished with sliding mechanics. PROGRESS intraoral photographs (Figure 6) were obtained nine months into treatment.

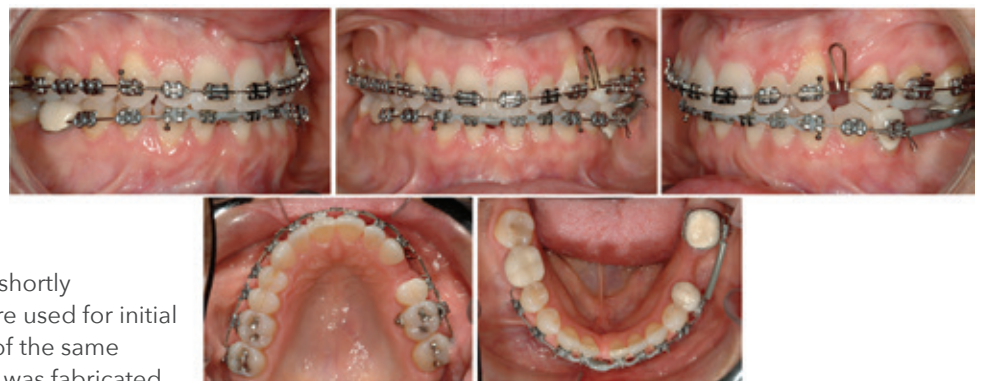

Figure 6: Progress intraoral photographs

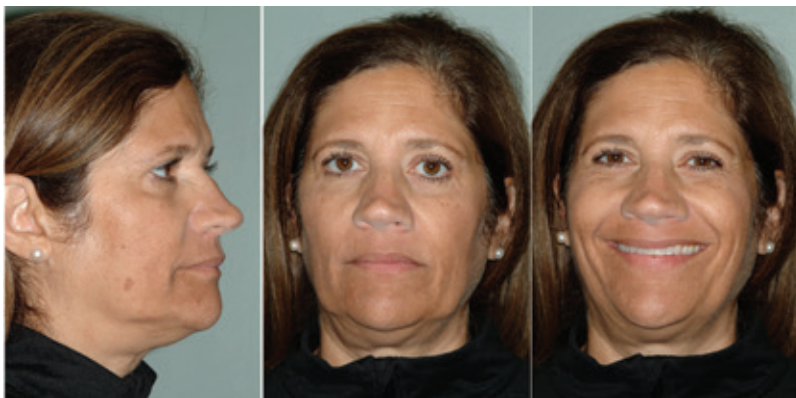

Figure 7: Final facial photographs

A rectangular stainless steel arch wire was ultimately placed in the mandibular arch, with open coiled spring in the left first molar position, and supported with Class II elastics. Cross bite elastics were also used briefly to coordinate the arches. After maxillary space closure, a square stainless steel arch wire was used for finishing. The maxillary left canine was stepped down for esthetics, stability of correction, and canine guidance. Total time in orthodontic treatment was 22 months.

The FINAL facial photographs (Figure 7) illustrate no change in frontal or profile appearance. Upon smiling, the difference in the maxillary posterior vertical display is still detectable but not obviously worse. The maxillary dental midline is improved, as is the angulation of the central incisors relative to the mid facial axis.

The FINAL intraoral photographs (Figure 8) show good alignment of the teeth in both arches, Class I canine occlusion bilaterally, and space closure in all but the mandibular left quadrant as planned. In fact, the size of this space was increased with uprighting of the adjacent second molar and mesial movement of the canine with Class II correction. Vacuum-formed retainers were provided for immediate retention, stability of space closure, and maintenance of alignment. The mandibular retainer will be replaced after restorative replacement of the left first molar.

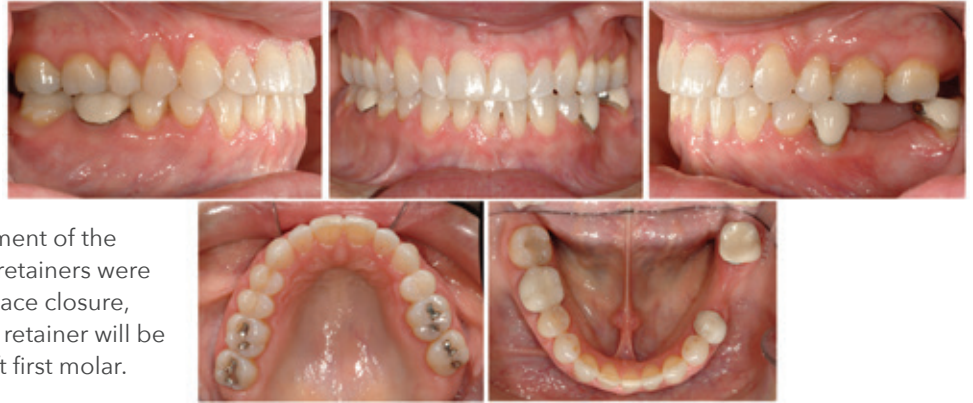

Figure 8: Final intraoral photographs

The post-treatment panoramic radiograph (Figure 9) shows good root parallelism across both extraction sites that were closed, and uprighting of the mandibular left second molar. Root quality and periodontal support remain excellent in this 57 year-old woman.

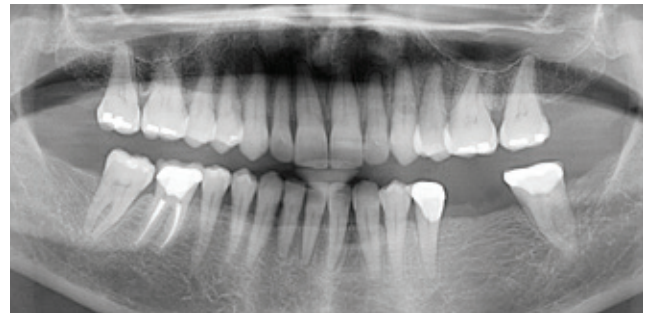


Figure 9: Post-treatment panoramic radiograph

The post-treatment cephalogram, its tracing and the cephalometric values (Figure 10a and 10b) reveal no significant change in any skeletal or dental measurements. The pre-treatment/post-treatment superimposition (Figure 11) confirms little difference. The maxillary incisor inclination is slightly improved, despite the asymmetric extraction treatment.

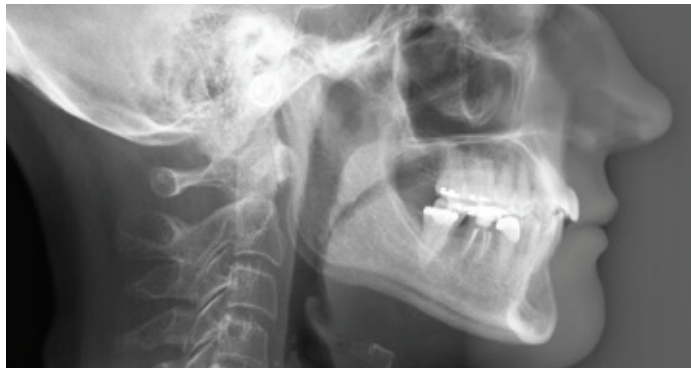

Figure 10a: Post-treatment cephalometric radiograph

Value	Norm	Std Dev	Dev Norm
86.3	82.0	3.5	1.2 *
82.5	79.0	3.5	1.0 *
3.8	3.0	2.5	0.3 *
88.2	95.0	7.0	-1.0 *
134.5	132.8	5.5	2.1 **
43.8	47.0	5.5	-0.7 *
3.8	2.7	1.7	-1.1 *
27.6	32.9	5.2	-1.0 *

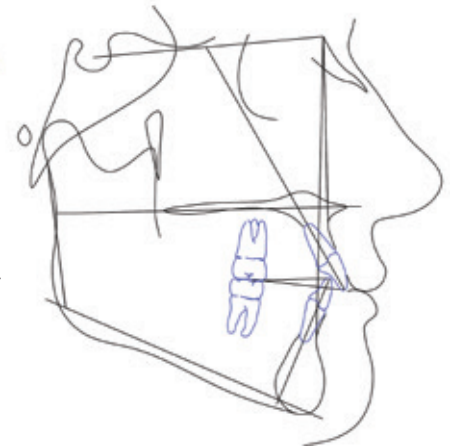


Figure 10b: Post-treatment cephalometric Analysis

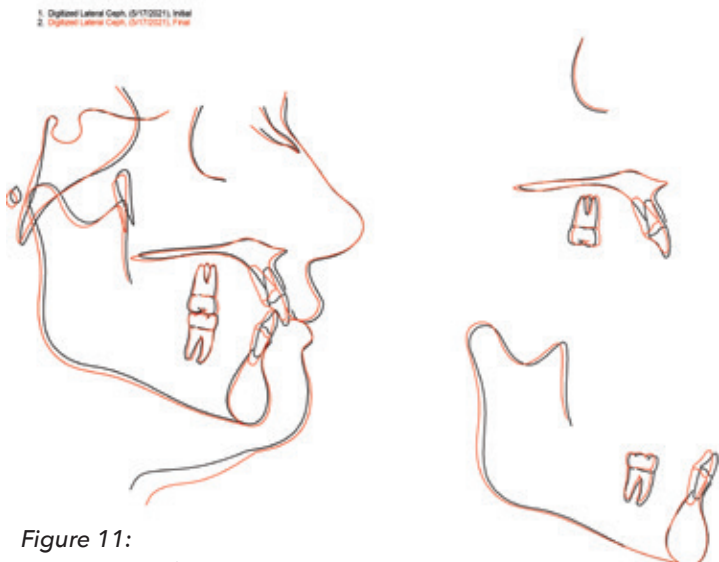


Figure 11: Pre-treatment/post-treatment superimposition

YOU may have treated this patient differently, and that is completely acceptable. This case report is presented to illustrate one way and to highlight the importance of listening to the patient to determine their primary concerns and preferences. This is particularly true in such cases where there are different acceptable treatment options and a lack of universal agreement between general dentists and specialists. It is critically important to find out what the patient wants. ■

Counter Clockwise Rotation of the Maxilla: An effective treatment option for Sleep Apnea with preservation of facial characteristics.

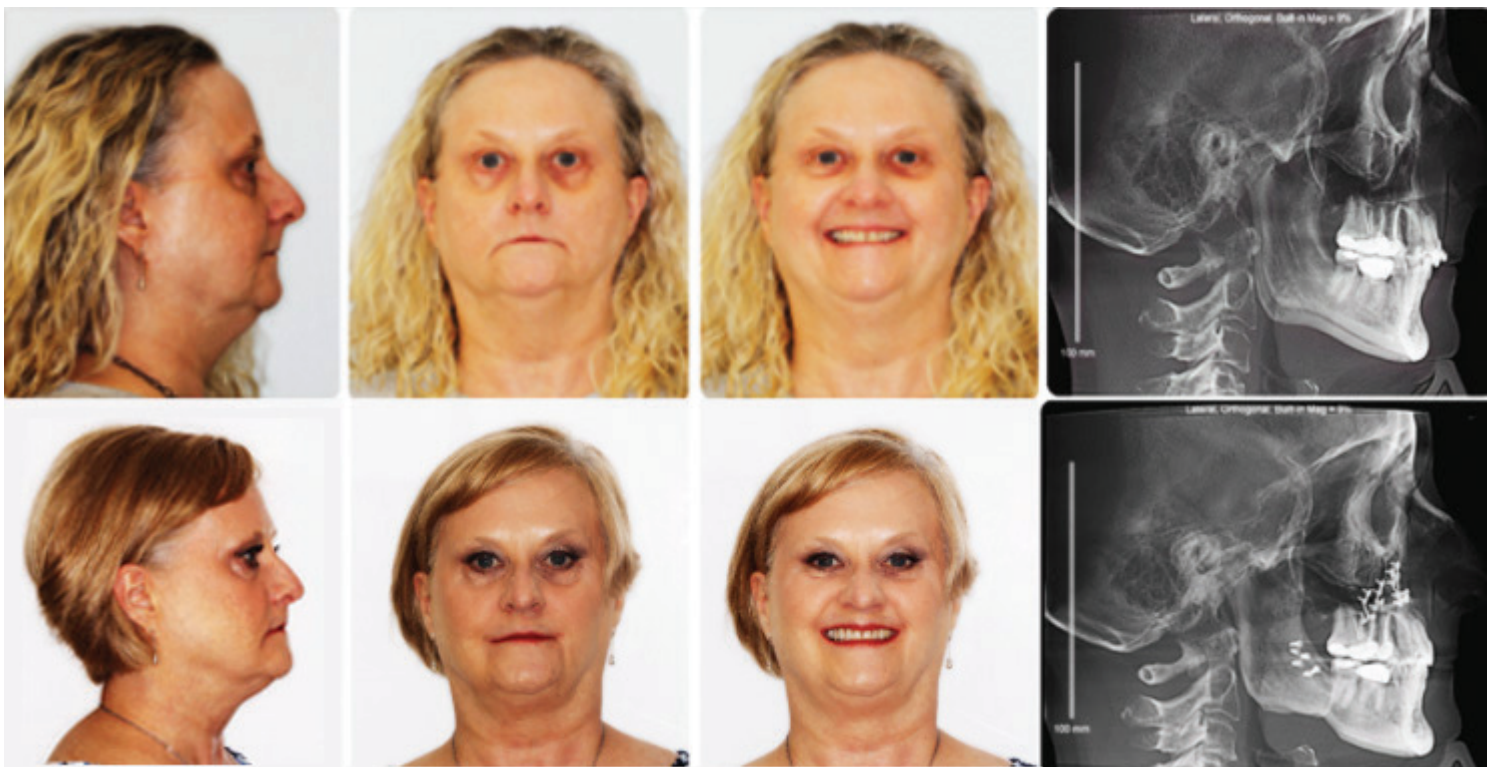Dr. Naurine Shah

The research described in this article was done in the Orthodontic Department at the University of Alabama. The project received funding from The Southern Association of Orthodontists.

Modern day ailments have seen an increase in Obstructive Sleep Apnea (OSA) which is defined as a pause in breathing during sleep, with subsequent arousal or oxygen desaturation. The incidence of OSA is 2-4 % in men, 2 % in women and 5-10 % in adults⁽¹⁾. Good sleep has been shown to play a huge role in recovery from everyday stresses and is therefore fundamental for the health of an individual. The common and gold standard for treatment of OSA is continuous positive airway pressure with a medical device pump assembly (CPAP)⁽²⁾. Patients often require lifelong treatment⁽³⁾ but 25-50% of patients have difficulty accepting this treatment due to a variety of reasons⁽⁴⁾. The most important deterrent is the cumbersome equipment that is involved and the inconvenience that comes with it. It has been reported that OSA may be improved by surgical forward movement of the maxilla and mandible, with subsequent improvement of airway volumes, thereby eliminating the need for CPAP⁽⁵⁾. However, this may compromise the facial esthetics

of patients who receive no benefit from a more protrusive profile. OSA may be treated with counter clockwise rotation of the mandible (CCW)⁽⁶⁾, combined with maxillo-mandibular advancement or by conventional advancement of the jaws as a first choice⁽⁷⁾. In the grand scheme of things this may be an excellent option for patients who want to stop the CPAP and find a permanent solution that does not involve wearing a mask tightly fitted to the face while sleeping, an activity that is so essential to human body survival.

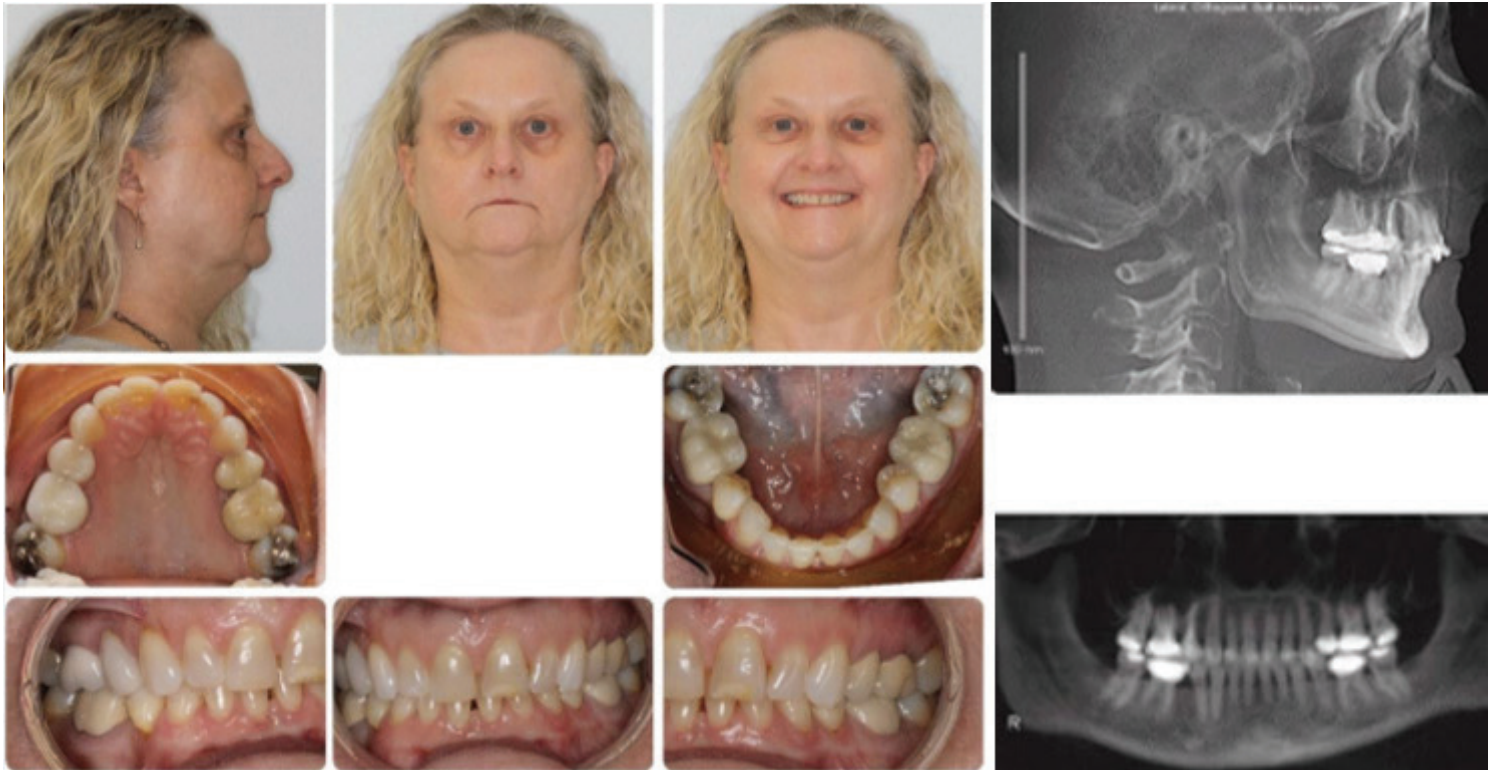Everyday we come across patients who have been diagnosed with OSA and who have been given the options of treatment, some of which are not applicable to every facial type. More and more research is now being directed towards finding the most non invasive option. Although CPAP is the gold standard, mandibular advancement devices and even myofunctional therapy⁽⁸⁾ have been shown to be effective.



If a patient has already tried the gold standard and is intolerant of it, what are some of the parameters that can be used to access the option of maxillofacial surgery? Will the patient's profile allow the drastic change needed for surgical correction? Please observe the records of the following patient.

The 57 year old female patient was referred to an oral surgeon by her sleep physician for an evaluation. Her main concern was the 'Inability to tolerate the CPAP' prescribed for sleep apnea. She was in search of an alternative because she felt claustrophobic with the mask of the CPAP and would often wake up feeling like she was 'drowning'. The patient denied difficulty staying awake driving or

watching movies but was unable to stay awake when reading. She reported fatigue and daytime sleepiness, trouble falling asleep with the mask on and waking up tired most mornings. The patient had a history of adenoidectomy, uvulopalatopharyngoplasty as well as a sleep endoscopy which demonstrated anterior posterior collapse at the level of the palate and circumferential collapse at the level of the base of the tongue. She also had undergone a turbinoplasty procedure and currently had a Mallampatti score of III⁽⁹⁾. An initial sleep test confirmed the sleep quality relationship to her AHI, but no other clinical questionnaires or tests were performed at her sleep physician's office.



Clinical examination revealed a convex facial profile, partially retrognathic and normo-divergent mandible and a retrusive chin on a skeletal class II base. Orthodontically, she had a stable class I molar and canine bilaterally with an over-jet of 3mm, an over-bite of 4 mm and mild crowding in both arches. The maxillary midline was co-incident with the facial midline and mandibular midline was shifted 3 mm to the right. Records consisted of photographs, panoramic and cephalogram radiographs as well as a CBCT scan. Lateral cephalometric analysis confirmed the occlusal class II deformity with an SNB of 74.6 degrees. The CBCT showed no abnormalities other than those described above.

Surgical management options included a combined orthodontic and orthognathic approach to help with resolution of the sleep apnea symptoms. Goals included improving AHI, while maintaining an esthetically acceptable profile and attaining a stable functional occlusion. Time management was an important factor because the patient was intolerant of the CPAP and the quality of her sleep was being adversely affected. She was too tired to carry out day to day function. Surgery with minimum presurgical orthodontics was therefore planned.

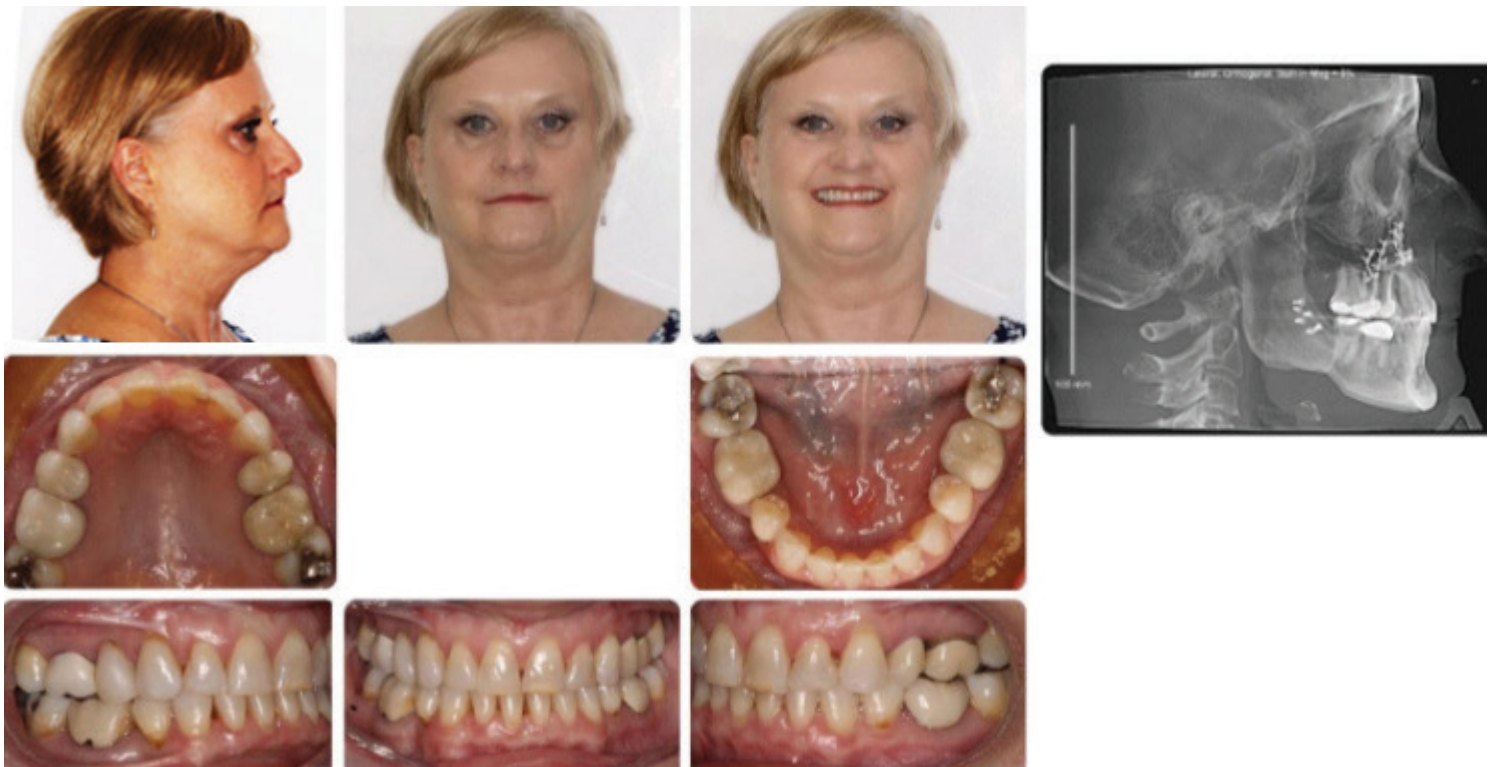Orthodontically, the dental, skeletal and soft tissue objectives for this patient were to assist the OMFS surgeon in preparing the patient for surgery in an expedited treatment time. This treatment included:

1. Placement of self ligation brackets (American Orthodontics Empower Clear) in the maxillary dentition only
2. A short 2 visit orthodontic treatment that included creation of space distal to the maxillary laterals to create an over-jet
3. Placement of mandibular brackets the day before surgery
4. Post-surgery overbite correction and elimination of crowding
5. Inter-arch mechanics after Bilateral Sagittal Split Osteotomy (BSSO) and counter clockwise rotation of the maxilla
6. Maintenance of the anterior-posterior (A-P) relationship with the use of inter arch mechanics after surgery
7. Detailing and finishing orthodontics
8. Retention

The final treatment plan consisted of non-extraction in the maxillary and mandibular arches and fixed appliances. There would be a short interval of presurgical fixed orthodontic appliances, followed by Lefort 1 down fracture of the maxilla, counter clockwise (CCW) rotation of the maxilla, BSSO with septoplasty and post-surgical orthodontic treatment to correct

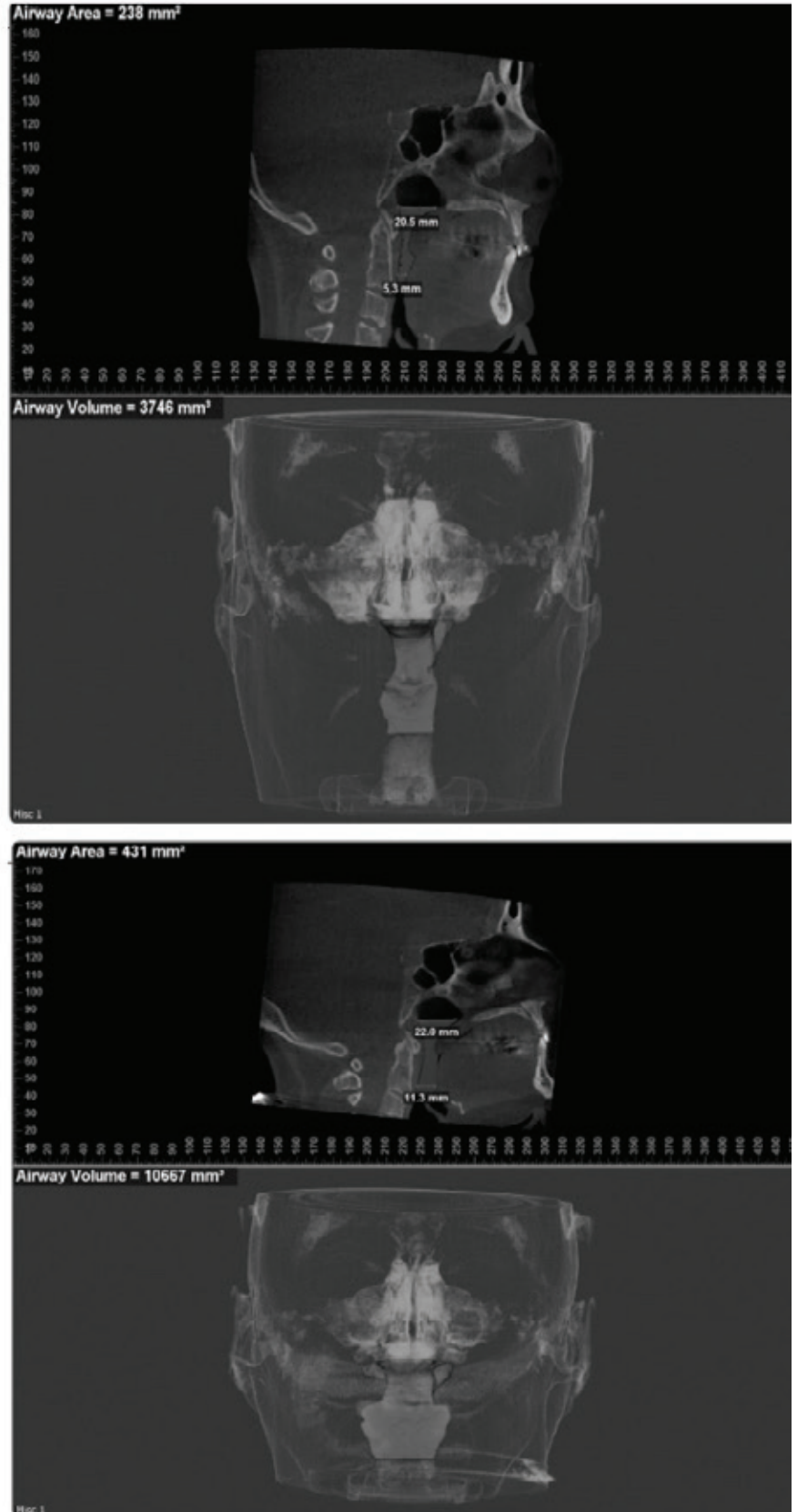
minor discrepancies. The surgical goals included increase in the airway parameter due to CCW of the maxilla and as well as mandibular advancement. These procedures would result in advancement of the soft palate and projection of the chin anteriorly⁽¹⁰⁾. Careful assessment of the preoperative airway volume was done using the DICOM file and a thorough cephalometric analysis was completed. Airway assessment was recorded at the narrowest cross-sectional point (in the sagittal plane) at two levels. The retropalatal level (RP) was found to be 20.5 mm and the retro lingual level (RL) was found to be 5.3 mm. These measurement areas were defined by Boyd⁽¹¹⁾. The total volume of the airway between (RL) and (RP) was measured to be 3746-millimetre square. Preoperative virtual surgical planning (VSP) was performed and measurements of the end results after surgery predetermined. The advent of virtual surgical planning (VSP) through computer-aided design (CAD) and computer-aided manufacturing (CAM) techniques has offered an alternative workflow⁽¹²⁾ for more precise preoperative planning and a decreased likelihood for intraoperative trial and error. This was an important step for a number of reasons which included:

1. A clearly discussed plan to maximize the patient's facial esthetics and goals for the OSA
2. A definitive occlusal plan since minimal orthodontics was carried out prior to surgery
3. A discussion of the smile esthetics after treatment

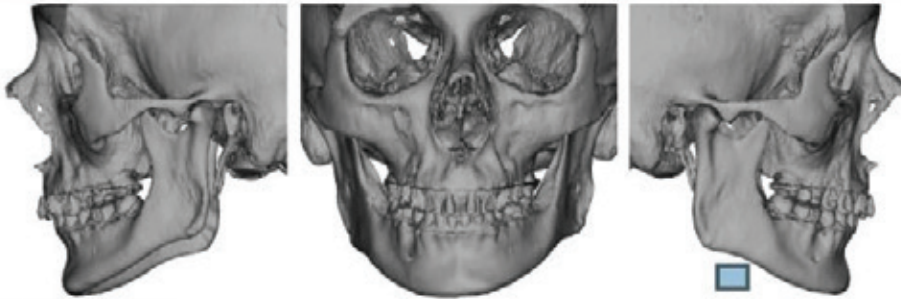

As a result of the on-line VSP conference, a CCW rotation of the maxillary plane of 6 degrees was anticipated. The occlusal plane was treatment planned to be flattened and the AP position of the maxilla maintained with no change to the alar base, therefore no compromise to facial esthetics was anticipated.

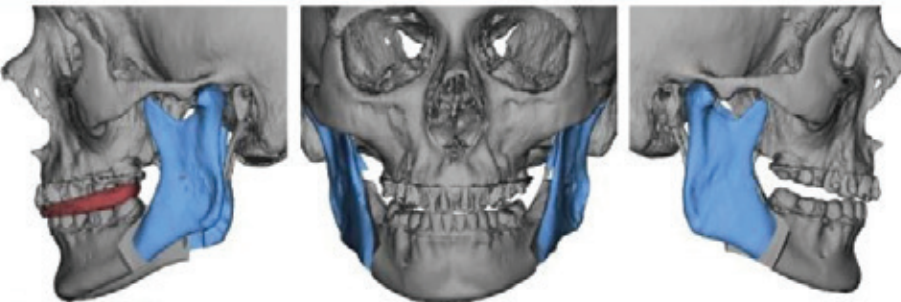
A Class I occlusion with normal overbite and over jet was achieved with coincident dental midlines to the mid-sagittal plane. A straight soft tissue profile with competent lips and an esthetically pleasing smile arc with an adequate gingival display was accomplished. The airway cross sectional area at the narrowest point in the sagittal plane at the level of retropalatal (RP) increased to 22 mm from 20.5 mm and retro lingual (RL) area increased to 11.3 mm from 5.3 mm with a total increase in airway volume to 10667 millimeter cube from 3746 millimeter cube. VSP planned changes were confirmed in the frontal plane, the occlusal plane and in the orientation of proximal and distal segments⁽¹⁴⁾. The counter clockwise rotation of the maxilla was achieved with differential anterior impaction of the maxilla, followed by maxillary advancement with rotation centers at the buttresses in order to maintain the profile. Mandibular advancement, which is the key to changes in airway, was therefore possible with minimum change to the profile. The patient reported improvement in sleep patterns and commented on how she was much more rested upon awakening. She also reported satisfaction with her facial esthetics and with the improvement of her profile. ■



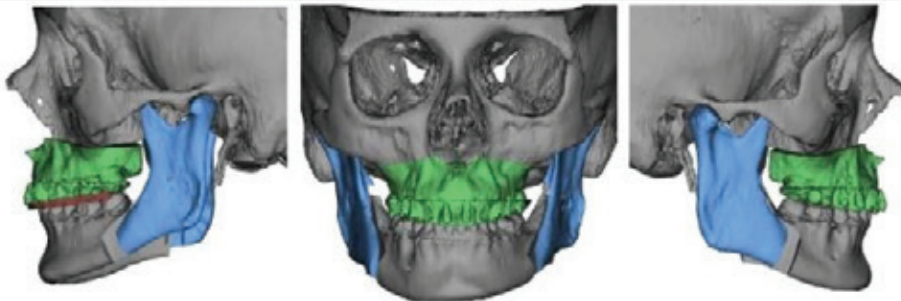
Preoperative Position



Intermediate Position



Postoperative Position



1. Holty JE, Guilleminault C. Maxillomandibular advancement for the treatment of obstructive sleep apnea: a systematic review and meta-analysis. *Sleep Med Rev.* 2010;14(5):287-97.
2. Campbell AJ, Reynolds G, Trengrove H, Neill AM. Mandibular advancement splint titration in obstructive sleep apnoea. *Sleep Breath.* 2009;13(2):157-62.
3. Metes A, Hoffstein V, Direnfeld V, Chapnik JS, Zamel N. Three-dimensional CT reconstruction and volume measurements of the pharyngeal airway before and after maxillofacial surgery in obstructive sleep apnea. *J Otolaryngol.* 1993;22(4):261-4.
4. Chen H, Lowe AA, de Almeida FR, Fleetham JA, Wang B. Three-dimensional computer-assisted study model analysis of long-term oral-appliance wear. Part 2. Side effects of oral appliances in obstructive sleep apnea patients. *Am J Orthod Dentofacial Orthop.* 2008;134(3):408-17.

5. Goodday RH, Bourque SE, Edwards PB. Objective and Subjective Outcomes Following Maxillomandibular Advancement Surgery for Treatment of Patients With Extremely Severe Obstructive Sleep Apnea (Apnea-Hypopnea Index >100). *J Oral Maxillofac Surg.* 2016;74(3):583-9.
6. Mehra P, Downie M, Pita MC, Wolford LM. Pharyngeal airway space changes after counterclockwise rotation of the maxillomandibular complex. *Am J Orthod Dentofacial Orthop.* 2001;120(2):154-9.
7. Li KK. Maxillomandibular advancement for obstructive sleep apnea. *J Oral Maxillofac Surg.* 2011;69(3):687-94.
8. Camacho M, Certal V, Abdullatif J, Zaghi S, Ruoff CM, Capasso R, et al. Myofunctional Therapy to Treat Obstructive Sleep Apnea: A Systematic Review and Meta-analysis. *Sleep.* 2015;38(5):669-75.

9. Lin HC, Lai CC, Lin PW, Friedman M, Salapatas AM, Chang HW, et al. Clinical Prediction Model for Obstructive Sleep Apnea among Adult Patients with Habitual Snoring. *Otolaryngol Head Neck Surg.* 2019;194599819839999.
10. Raffaini M, Pisani C. Clinical and cone-beam computed tomography evaluation of the three-dimensional increase in pharyngeal airway space following maxillo-mandibular rotation-advancement for Class II-correction in patients without sleep apnoea (OSA). *J Craniomaxillofac Surg.* 2013;41(7):552-7.
11. Boyd SB, Walters AS, Song Y, Wang L. Comparative effectiveness of maxillomandibular advancement and uvulopalatopharyngoplasty for the treatment of moderate to severe obstructive sleep apnea. *J Oral Maxillofac Surg.* 2013;71(4):743-51.
12. Foley BD, Thayer WP, Honeybrook A, McKenna S, Press S. Mandibular reconstruction using computer-aided design and computer-aided manufacturing: an analysis of surgical results. *J Oral Maxillofac Surg.* 2013;71(2):e111-9.
13. Souccar NM, Bowen DW, Syed Z, Swain TA, Kau CH, Sarver DM. Smile dimensions in adult African American and Caucasian females and males. *Orthod Craniofac Res.* 2019;22 Suppl 1:186-91.
14. Farrell BB, Franco PB, Tucker MR. Virtual surgical planning in orthognathic surgery. *Oral Maxillofac Surg Clin North Am.* 2014;26(4):459-73.



32 Lenox Pointe NE
Atlanta, GA 30324
Phone: (404) 261-5528

SAO&Education

SAO&Advocacy

SAO&Relationships

SAO&Charity

SAO&Governance

SAO&Teambuilding

SAO&YOU!

Join us for the party of the century



Centennial Celebration of the
Southern Association of Orthodontists

SEE YOU IN CHARLOTTE
OCTOBER 7-9, 2021